Orthopaedics & Traumatology: Surgery & Research 103 (2017) 269–273

Available online at
ScienceDirect
www.sciencedirect.com

Elsevier Masson France
EM|consulte
www.em-consulte.com/en

Original article

Distal femoral hemiepiphysiodesis using screw and non-absorbable filament for the treatment of idiopathic genu valgum. Preliminary results of 12 knees

G. Martínez [a,*], S. Drago [a], C. Avilés [b], A. Ibañez [a], F. Hodgson [a], C. Ramírez [a]

[a] Department of Traumatology and Orthopedics, Clinical Hospital of Pontificia Universidad Católica de Chile, Santiago, Chile
[b] Faculty of Medicine, Pontificia Universidad Católica de Chile, Santiago, Chile

ARTICLE INFO

Article history:
Received 30 June 2016
Accepted 2 November 2016

Keywords:
Growth plate
Epiphysiodesis
Genu valgum
Child

ABSTRACT

Introduction: Different techniques for gradual correction of angular deformities of lower limbs exist. Screws and nonabsorbable filament has been described as an effective alternative for transitory hemiepiphysiodesis in New Zealand rabbits.
Hypothesis: Hemiepiphysiodesis using screws and non-absorbable filament is effective in pediatric population, for correction of genu valgum.
Methods: Retrospective evaluation, 12 knees in 6 patients younger than 15 years (3 female), operated because of genu valgum. An anchoring system with two 4.0 mm cancellous screw with metal washer joined by FiberWire #2.0 filament. Initial and final intermalleolar distance (IMD) and mechanical lateral distal femoral angle were compared, recording complications. Mann–Whitney test was used for statistics, with significance value <0.05.
Results: All patients achieved the expected correction. IMD and mLDFA were significatively improved. Only one patient presents a minor perioperative complication.
Discussion: Lateral distal femoral hemiepiphysiodesis with screws and nonabsorbable filament resulted to be an effective alternative for genu valgum gradual correction in pediatric population. This is the first article that proposes this model, as an efficient and simple alternative for the treatment of genu valgum in pediatric patients.
Level of evidence: Retrospective study, Level IV.

© 2017 Elsevier Masson SAS. All rights reserved.

1. Introduction

Angular deformities of the lower limbs are a common finding in children [1]. Although most of these correspond to physiological conditions that resolve spontaneously without intervention [2–4], some deformities persist to preadolescence and will not correct spontaneously [5]. In these cases, surgical intervention may be needed to restore the mechanical axis of the lower limbs. The current recommendation is to address lower limb angular deformities as early as possible to prevent consequences as an altered gait pattern, early degeneration of the articular cartilage and soft tissue changes [5–7].

Different techniques for gradual correction of angular deformities of lower limbs exist [7–9]. One of them is hemiepiphysiodesis, which consists in partial growth arrest of one side of the physis in order to cause a secondary angular modification, gradually correcting the deformity [9,10]. The ideal method for hemiepiphysiodesis would be one that ensures a controlled rate of correction without causing permanent physeal damage, unless the objective is to cause a permanent physeal closure. These techniques include permanent methods such as ablation or physeal curettage [11] or potentially reversible techniques such as stapling [12], transphyseal screws [13] or tension band plates [14]. The most currently used is the tension band plate with two screws [14–16].

Gil et al. studied the use of screws and absorbable filament as hemiepiphysiodesis fixing method in a New Zealand rabbit model, proving to be an effective technique for angular modification of lower limbs [17]. In a recent study, Martinez et al. demonstrated that the use of screws and nonabsorbable filament causes a significant angular modification of lower limbs in New

* Corresponding author at: Marcoleta 352 interior, 2do piso, Santiago, Región Metropolitana, CP 8330033, Chile.
E-mail address: ginomartinez@gmail.com (G. Martínez).

http://dx.doi.org/10.1016/j.otsr.2016.11.014
1877-0568/© 2017 Elsevier Masson SAS. All rights reserved.

Zealand rabbits [18]. They also showed that the removal of the sutures restored physeal growth, proving that is an alternative for transitory hemiepiphysiodesis in patients with angular deformity of lower limbs.

Given favorable results in animal models, this technique appears as an alternative to tension band plates. The proposed method allows physeal arrest to be easily removed by cutting the filament, even under local anesthesia. This technique also represents a much cheaper alternative to traditional implants (approximately USD 30 vs. USD 1000 in our center), what is a particularly important issue in developing countries, where public health systems have a limited budget.

The effectiveness and safety of hemiepiphysiodesis with screws and non-absorbable filament for genu valgum correction has not been previously studied in pediatric population. We did a retrospective evaluation of patients under 15 years, with idiopathic genu valgum treated with hemiepiphysiodesis with screws and non-absorbable suture. Our hypothesis was that hemiepiphysiodesis using screws and non-absorbable filament is effective in pediatric population, for correction of genu valgum.

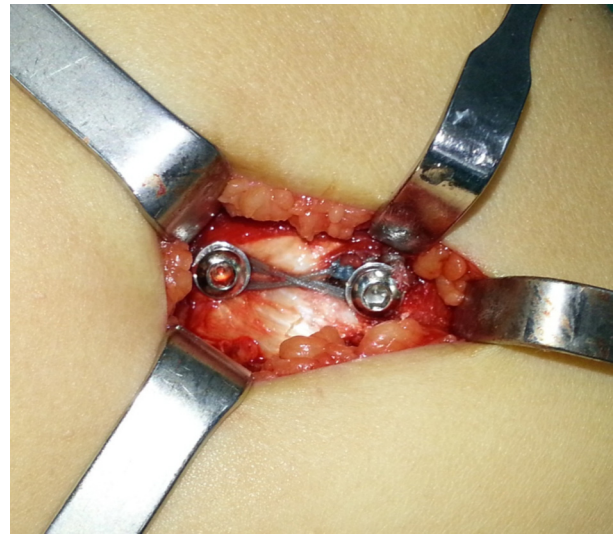

Fig. 1. Intraoperative image of hemiepiphysiodesis with screws and non-absorbable filament.

2. Patients and methods

2.1. Study design

Case report, using clinical and radiographic follow-up data of patients that underwent distal femoral hemiepiphysiodesis using screws and nonabsorbable filament. Were included in the study: boys and girls between 8 and 15 years old, with diagnosed idiopathic genu valgum. Our diagnostic algorithm was the following: when patients older than 8 years came to our clinic because of discomfort associated to genu valgum, we measured the clinical intermalleolar distance (IMD), if it was more than 8 cm, then we requested anteroposterior X rays of lower extremities in standing position. If the mechanical axis of the limb was within zones 2 or 3, we measured the articular angles. If the deformity was categorized as driven by distal femur, with a mechanical lateral distal femoral angle (mLDFA) <87°, the surgical option was lateral hemiepiphysiodesis of distal femur. Were excluded: patients with skeletal dysplasias, osteodystrophy, physeal injury or previous surgeries around the knee. Patients who were still in correcting process at the time of the study were also excluded (open physis with implants in situ). The data collection was approved by the Research Ethics Committee of our institution.

Surgery was performed in nine patients, six of which met the follow-up established criteria, three boys and three girls. The median age was 11 years (range 8–14 years). The median time between surgery and the final measure angular correction was 12 months (range 11–13 months).

2.2. Surgical procedure

An anchoring system with two 4.0 mm cancellous screw and metal washer was used. The two monocortical screws were implanted on the medial aspect of the distal femur under radioscopic vision: one proximal to the physis and other distal to the physis. The screws were tied together using a nonabsorbable filament (FiberWire #2.0), with 2 laps going under the washers and following a pattern in a figure of eight (Figs. 1 and 2). These washers are used to prevent sliding of the filament over screw head. Any periosteal damage was carefully avoided. The procedure was performed by the same surgeon (GM) in all patients.

2.3. Data collection

Clinical and radiographic collecting was performed. We analyzed the radiographs taken at the beginning, at the end of treatment (physeal closure or final angular correction) and posterior to fixation removal when necessary. Data of gender, age at diagnosis and intervention were recorded. Clinical IMD modification, mechanical axis correction and mLDFA were evaluated using long cassette radiographies (Fig. 3). Angular measurements were performed by two physicians working blindly and independent to the main surgeon (a pediatric orthopedic surgeon and a trained orthopedic resident). Each of them performed two repeated measurements in different moments of time and then considering an average value of the data. Surgical time, operative and postoperative complications were recorded.

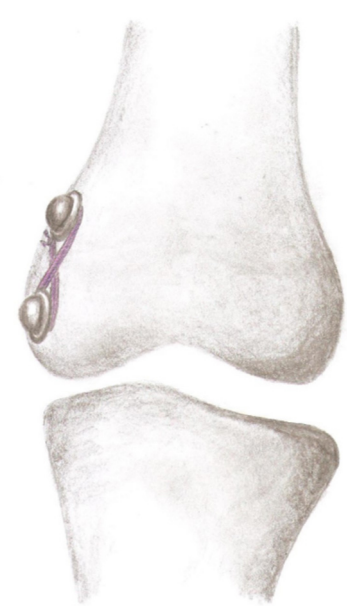

Fig. 2. Scheme of hemiepiphysiodesis with screws and non-absorbable filament.

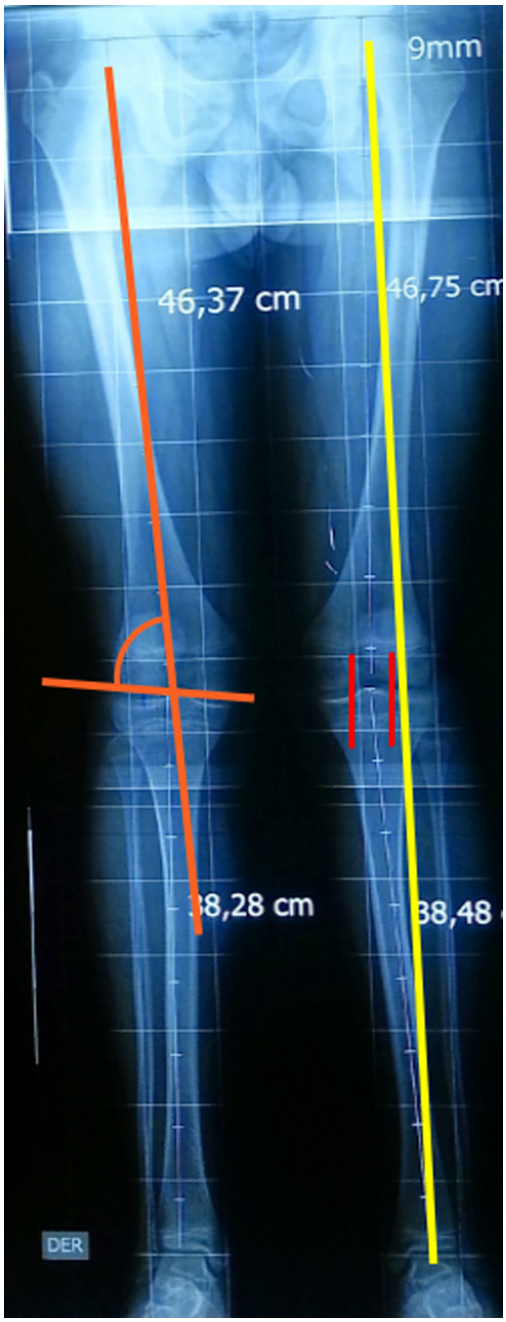

Fig. 3. Radiographic measurements used: mechanical axis in zone 2 (yellow), mLDFA (orange).

2.4. Statistical analysis

Statistical analysis was performed using the Mann–Whitney test for nonparametric variables with Prism program. A significance value <0.05 was used. Intra and interobserver variation of mLDFA measurements was analyzed with intra-class correlation test (ICC).

3. Results

All patients achieved the expected correction, with mechanical axis within zone 1 at the end of treatment (axis between tibial spines). Clinical IMD significantly changed from an initial median of 10.5 cm (range 9.0–15.0 cm) to a final median of 3.5 cm (range 1.0–6.5 cm), $P < 0.0022$ (Figs. 4 and 5).

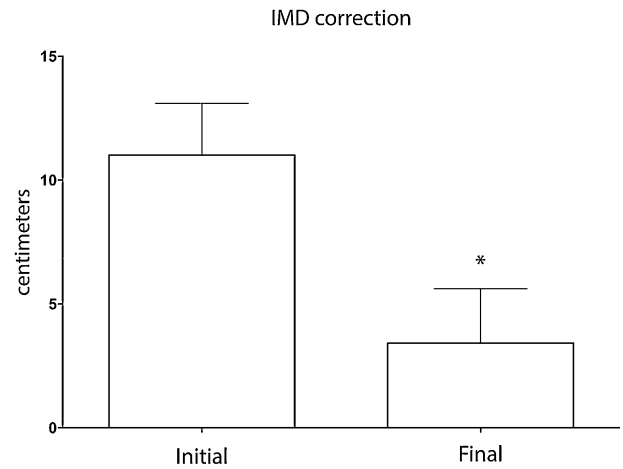

Fig. 4. Variation of clinical IMD.

The mLDFA significantly changed from an initial median of 84.1° (range 81.6–86.3°) to a final median of 90.5° (range 87.0–94.8°), $P < 0.0001$ (Figs. 6 and 7). When assessing mLDFA modification of each lower limb individually, a significant correction is also obtained. For mLDFA measurements, good interobserver correlation coefficient was found (ICC = 0.89), as well as excellent intraobserver correlation for the orthopedic resident (ICC = 0.95) and for pediatric orthopedic surgeon (ICC = 0.98). The median of mLDFA correction velocity was 0.55 degrees/month (range 0.43–0.71 degrees/month).

Only one patient presented a minor perioperative complication, corresponding to a small surgical wound dehiscence which evolved favorably toward closure with simple cures. The median of length of surgery for each knee was 15 min (range 13–18 min). Table 1 summarizes IMD and mLDFA measurement of each lower limb and its respective final corrections for each patient.

Three patients completed the desired correction while still having open physis, so it was necessary to cut the filament. This procedure was performed in an operating room with local anesthesia and sedation, leaving the screws in situ. Two of them presented a discrete valgus recurrence (rebound effect), remaining the axis

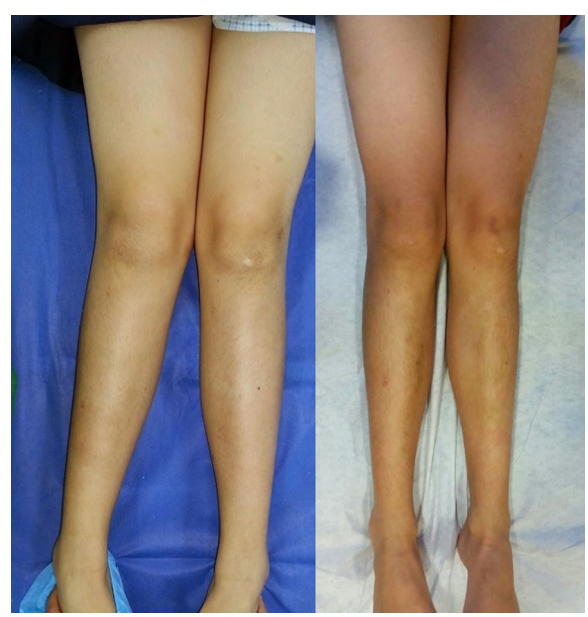

Fig. 5. Clinical IMD correction example: preoperative (left) and postoperative (right).

Table 1
Summary of clinical and radiographic measurements.

Patients	Clinical IMD (cm)		Right mLDFA (°)		Left mLDFA (°)		Final correction		
	Initial	Final	Initial	Final	Initial	Final	IMD (cm)	Right mLDFA (°)	Left mLDFA (°)
N1	15.0	6.5	81.6	87.0	84.0	87.3	8.5	5.4	3.3
N2	9.0	3.0	85.0	91.7	84.2	91.0	6.0	6.8	6.9
N3	11.0	1.0	86.3	93.6	86.0	93.5	10.0	7.3	7.5
N4	10.0	4.0	84.0	90.0	83.1	88.7	6.0	6.0	5.6
N5	11.0	5.0	83.0	88.6	83.0	88.8	6.0	5.6	5.8
N6	10.0	1.0	85.6	94.8	85.4	94.2	9.0	9.1	8.8

IMD: intermalleolar distance; mLDFA: mechanical lateral distal femoral angle; der: derecho; izq: izquierdo; cm: centimeters; °: degrees.

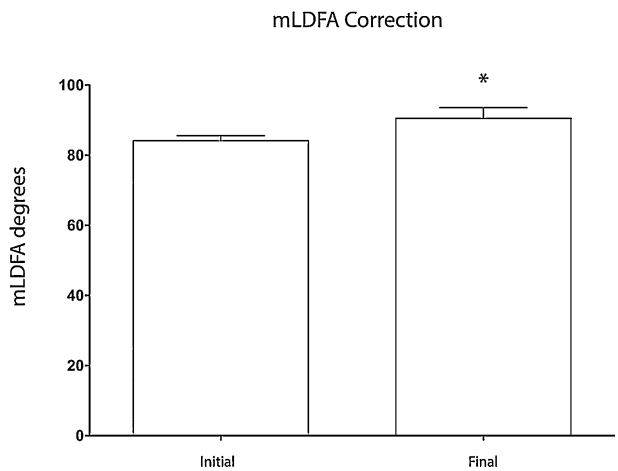

Fig. 6. Correction of mLDFA in both limbs together.

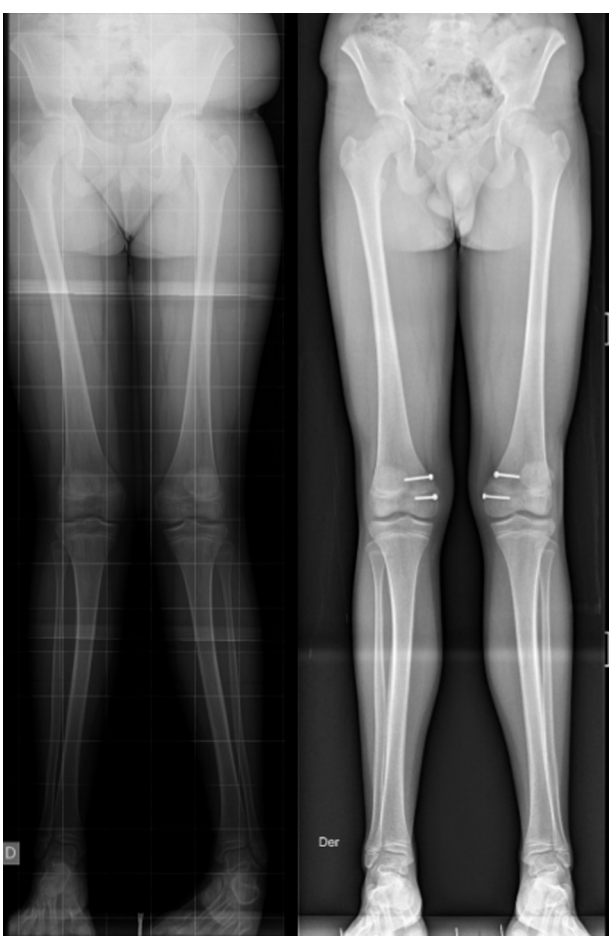

Fig. 7. mLDFA correction example: preoperatively (left) and postoperative (right).

within zone 1 at the last control with closed physis. The third patient still remains with open physis and maintains correction without rebound.

4. Discussion

The treatment of angular deformities of lower limbs is an active field of research. The use of absorbable and nonabsorbable filament as hemiepiphysiodesis fixation method has been studied in animal models, proving to be an effective technique for angular modification of the lower limbs and keeping the physeal function intact at the time of filament removal [17,18]. To our knowledge, there are no previous reports in the literature that have evaluated this technique in humans.

In our report, the lateral distal femoral hemiepiphysiodesis with screws and nonabsorbable filament proved to be an effective and safe method for angular correction of genu valgum in pediatric patients. This procedure resulted in the expected correction in all patients, with no major perioperative complications, so it is presented as an efficient alternative for transitory hemiepiphysiodesis in patients with angular deformity of the lower limbs.

Our study presents promising results on an homogeneous group of patients with idiopathic genu valgum surgery. The technique has also been successfully applied by our group in patients with genu valgum by osteochondromatosis and other skeletal dysplasias, genu varum and genu recurvatum, but these are unreported cases, thus, we can not make conclusions about this and further research is needed.

The proposed model is a useful, effective and cheaper alternative to the current standard of care (approximately USD 30 vs. USD 1000 in our center), which is a particularly important issue in public health systems with limited budget or in developing countries. In addition, the versatility of the system can be adapted to different geometry and different sizes of physis (the plates are made for specific geometry and bone size). If there is need to remove the fixation, this can be done easily only by cutting the filament with a scalpel, which could be performed even under local anesthesia. The screws may eventually be left for sequential correction. This model has the limitation that the tension of the filament is not standardized because we do not count with a meter for this, thus, the tension can be variable.

Similar to animal studies with the technique [18], in our series the subsequent rebound effect posterior to fixation removal was present, which states that the physis preserves its intact function after the transitory arrest. This phenomenon has also been clinically described with the use of tension band plates [14,15], and it is particularly important to consider when making corrections in patients with remaining growth potential, where a slight "overcorrection" to varus is recommended to avoid residual deformities after fixation removal.

Although this article has limitations of a retrospective study with a limited sample size without comparison to other method, it has the strength to be the first report of pediatric patients diagnosed

with genu valgum treated with distal femoral hemiepiphysiodesis using screws and nonabsorbable sutures. Further studies with greater number of cases evaluated will allow a formal comparison with other traditional methods used, and their potential application in others limb axis disorders.

5. Conclusion

Lateral distal femoral hemiepiphysiodesis with screws and nonabsorbable filament is an effective and safe method for correction of mechanical axis and IMD in genu valgum in pediatric patients. The proposed model is a cheaper alternative than the current standard of care for the treatment of genu valgum.

Funding

The authors declare no funding received for the work.

Disclosure of interest

The authors declare that they have no competing interest.

References

[1] Talarico V, Baserga M, Fuiano L, Mattace F, Mastria G, Arcuri V. Evaluation of the varus-valgus knee in a group of Calabrian children. Pediatr Med Chir 2011;33:80–4.
[2] Staheli L, Corbett M, Wyss C, King H. Lower extremity rotational problems in children. Normal values to guide management. J Bone Joint Surg 1985;67:39–47.
[3] Salenius P, Vankka E. The development of the tibiofemoral angle in children. J Bone Joint Surg Am 1975;57:259–61.
[4] Kling Jr TF, Hensinger RN. Angular and torsional deformities of the lower limbs in children. Clin Orthop Relat Res 1983;176:136–47.
[5] Murphy SB. Tibial osteotomy for genu varum. Indications, preoperative planning, and technique. Orthop Clin North Am 1994;25:477–82.
[6] Castañeda P, Urquhart B, Sullivan E, Haynes RJ. Hemiepiphysiodesis for the correction of angular deformity about the knee. J Pediatr Orthop 2008;28:188–91.
[7] Saran N, Rathjen KE. Guided growth for the correction of pediatric lower limb angular deformity. J Am Acad Orthop Surg 2010;18:528–36.
[8] Ballal MS, Bruce CE, Nayagam S. Correcting genu varum and genu valgum in children by guided growth. J Bone Joint Surg Br 2010;92:273–6.
[9] Phemister DB. Operative arrestment of longitudinal growth of bones in the treatment of deformities. J Bone Joint Surg 1933;15:1–9.
[10] Haas SL. Retardation of bone growth by a wire loop. J Bone Joint Surg Am 1945;27:25–36.
[11] Bowen JR, Torres RR, Forlin E. Partial epiphysiodesis to address genu varum or genu valgum. J Pediatr Orthop 1992;12:359–64.
[12] Blount WP, Clarke GR. Control of bone growth by epiphyseal stapling, a preliminary report. J Bone Joint Surg Am 1949;31A:464–78.
[13] Metaizeau JP, Wong-Chung J, Bertrand H, Pasquier P. Percutaneous epiphysiodesis using transphyseal screws (PETS). J Pediatr Orthop 1998;18:363.
[14] Stevens PM. Guided growth for angular correction: a preliminary series using a tension band plate. J Pediatr Orthop 2007;27:253–9.
[15] Burghardt RD, Herzenberg JE, Standard SC, Paley D. Temporary hemiepiphyseal arrest using a screw and plate device to treat knee and ankle deformities in children: a preliminary report. J Child Orthop 2008;2:187–97.
[16] Niethard M, Deja M, Rogalski M. Correction of angular deformity of the knee in growing children by temporary hemiepiphyseodesis using the eight-plate. Z Orthop Unfall 2010;148:215–21 [in German].
[17] Gil R, Gil J, Garrido R, Melgosa M, Lostale F, Morandeira J. Distal femoral hemiepiphysiodesis using absorbable materials. Rev Esp Cir Osteoart 2000;35:297–306.
[18] Martinez G, Baar A, Ibañez A, Vergara P, Carmona M, Drago S. Assessment of femoral physeal activity after transitory hemiepiphysiodesis using screws and nonabsorbable filament. J Pediatr Orthop 2014;34:208–12.